

11th AHEAD- GLTFCA working group meeting

Mopani, 2-4th March, 2001



Disease in free-ranging wildlife from the GLTFCA: Preliminary findings January 2009-Dec 2010

Dr Emily Lane

Wildlife Epidemiology Research Programme
National Zoological Gardens of South Africa

Drs R Bengis, L-M de Klerk-Lorist
Department of Agriculture, Fisheries and Forestry

Dr B Reininghaus
State Vet Mpumalanga

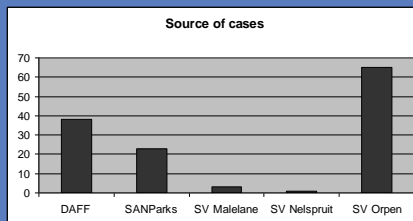
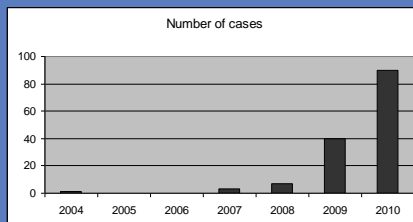
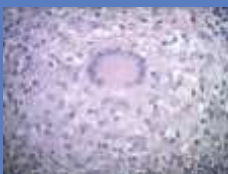Drs M Hofmeyr, P Buss and D Govender
SANParks

Dr A Michel
Faculty of Veterinary Science

Case breakdown



- 11 historic cases
- 130 current cases
 - 2009 (40)
 - 2010 (90)
 - 18 pending
- Source of cases
 - Within KNP (57)
 - Outside (72)
 - Zimbabwe (1)



Michel de Garine-Wichatitsky, et al. 2010. Letter to Editor: Spread of wildlife bovine tuberculosis across international boundaries of the Great Limpopo Trans Frontier Conservation Area. Emerging Infectious Diseases 16(5): 884-5

Species



African buffalo	20	Lion	22
Impala	11	Leopard	11
Black wildebeest	9	Spotted hyaena	5
Giraffe	2	Cheetah	1
Greater Kudu	4	African Wild Dog	1
Common duiker	1	Small spotted genet	2
Bushbuck	1	Serval	1
Zebra	8	Nile crocodile	10
White Rhino	8	Snouted cobra	1
Elephant	7	Chacma baboon	2
Pangolin	1	Black crowned Tchagra	1
Scrub hare	1	Swainsons Francolin	1
		Water dikkop	1

Bias

- = sampling choice
- = predation
- = autolysis

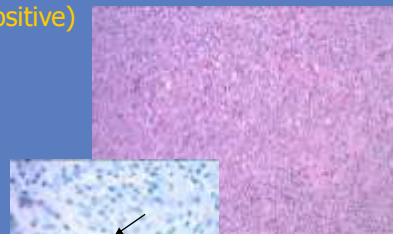
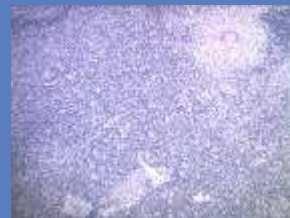Small sample size

Diagnoses

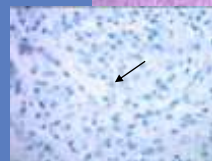


- African buffalo (20)
 - TB monitoring
 - 12 – histologically negative
 - 7 - histologically positive
 - Capture death
- Lion (22)
 - TB monitoring (11 histologically positive)
 - Old age/bite wounds
 - Starvation (neonate)
 - Problem animals (6)
 - Suspected FIV
 - Superficial necrolytic dermatitis
 - Peri-pancreatic necrosis

TB: lymph node



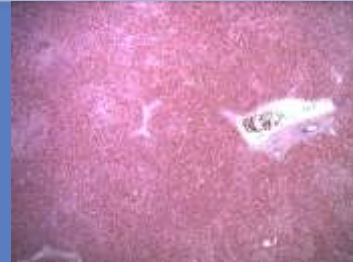TB: lung




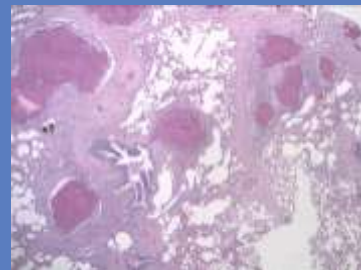
Diagnoses: 2



- White rhino (8)
 - Trauma (3)
 - Poaching
 - Microcystin toxicosis
 - Salmonella enteritis
 - Generalised lymphadenitis and pneumonia
 - Multiple lung microgranulomas



Liver: microcystin damage



TB diagnosis



- Ante-mortem
- Post-mortem
 - Cytology (ZN)
 - Histology (H&E, ZN, Fite Faraco)
 - PCR from embedded tissue
 - Culture and sequencing

Species	Histology	ZN	PCR	Culture	Sequencing
Buffalo	-ve	-ve	n/d	<i>M bovis</i>	KNP profile
Chacma baboon	-ve	-ve	+ve	n/d	n/d
Impala	+ve	+ve	+ve	<i>M bovis</i>	n/d
Leopard	+ve	+ve (FF +ve)	n/d	<i>M bovis</i>	n/d
Lion	-ve	-ve	+ve	<i>M bovis</i>	n/d

Diagnoses: 3



- Leopard (11)
 - Trauma (5)
 - Problem animals (3)
 - Notoedric mange
 - Tuberculosis (1)
- Spotted hyaena (5)
 - Traumatic injury (2)
 - Tuberculosis (1)
 - Hepatitis and encephalitis
 - Capture death



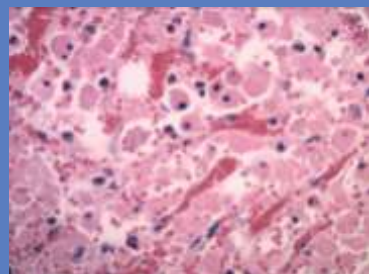
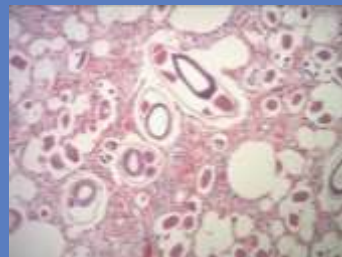Mange - Roy Bengis

Diagnoses: 4



- Impala (11)
 - TB monitoring
 - Histologically negative (4)
 - Histologically positive (1)
 - Trauma (3)
 - Parasitic dermatitis
 - Lung worm
 - Unknown (skin biopsy)
- Blue Wildebeest (9)
 - Microcystin toxicosis (6)
 - Corneal ulceration – cause unknown
 - Disease monitoring (2)
- Greater Kudu (4)
 - Tuberculosis (2)
 - Verminous cellulitis (2)

Lung worm



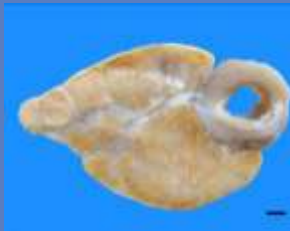Diagnoses: 5



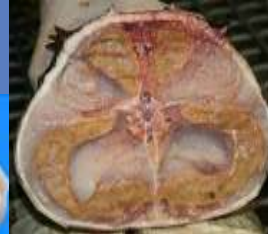- Zebra (8)
 - Microcystin toxicosis
- Nile crocodile (10)
 - Pansteatitis (10)
- Giraffe (2)
 - Sarcoids
 - Parasitic dermatitis
- Elephant (7)
 - Verminous cholangitis
 - Normal (4) – hunted
 - Traumatic injury (2)
- Chacma baboon (2)
 - Normal – problem animals

Roy Bengis

Publication submitted: Journal of Zoo and Wildlife Medicine



Pansteatitis

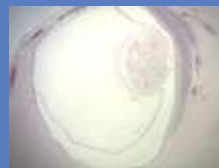

Sarcoids: Roy Bengis

Diagnoses: 6



- Small spotted genet (2)
 - Rabies
 - Trauma
- African wild dog
 - trauma
- Elephant (7)
 - Verminous cholangitis
 - Normal (4) – hunted
 - Traumatic injury (2)
- Bushbuck and common duiker
 - Cerebral tapeworms
- Serval, scrub hare, Water dikkop, Swainson's francolin
 - Road traffic accident
- Cheetah
 - Oesophageal tumour
- Snouted Cobra
 - Problem animal
- Pangolin
 - Poached
- Black crowned Tchagra
 - acute heart failure



Summary



- Benefits
 - Base line disease information
 - Species variation in disease presentation
 - Disease distribution
 - Case reports
 - Emerging diseases (non/infectious)
 - Management decisions
 - Trends
 - prospective research
 - Test validation
 - Forensics/law enforcement
 - Research
 - Saved samples and data – retrospective research



Acknowledgements



- United State Fish and Wildlife Service
 - funding
- Pathology Section, Department of Paraclinical Studies, Faculty of Veterinary Science, University of Pretoria
 - processing the histology slides
- Department of Agriculture, Forestry and Fisheries
 - Lab registration
- Onderstepoort Veterinary Institute
 - PCR analysis on formalin fixed tissues
- The veterinarians from SANParks, DAFF, and Mpumulanga
 - samples

